



Chapter V: Diabetic Foot

M. Lepäntalo^{a,b,*}, J. Apelqvist^{c,d}, C. Setacci^e, J.-B. Ricco^f, G. de Donato^e,
F. Becker^g, H. Robert-Ebadi^g, P. Cao^h, H.H. Ecksteinⁱ, P. De Rango^k,
N. Diehm^l, J. Schmidli^m, M. Teraa^{n,o}, F.L. Mollⁿ, F. Dick^m, A.H. Davies^p

^aDepartment of Vascular Surgery, Helsinki University Central Hospital, Helsinki, Finland

^bInstitute of Clinical Medicine, Faculty of Medicine, University of Helsinki, Helsinki, Finland

^cThe Diabetic Foot Center at the Department of Endocrinology, Skåne University Hospital, Malmö, Sweden

^dDivision for Clinical Sciences, University of Lund, Lund, Sweden

^eDepartment of Surgery, Unit of Vascular and Endovascular Surgery, University of Siena, Siena, Italy

^fDepartment of Vascular Surgery, University Hospital of Poitiers, Poitiers, France

^gDivision of Angiology and Hemostasis, Geneva University Hospitals, Geneva, Switzerland

^hUnit of Vascular Surgery, Department of Cardiosciences, Hospital S. Camillo-Forlanini, Rome, Italy

ⁱClinic for Vascular Surgery, Klinikum rechts der Isar, Technische Universität München, Munich, Germany

^kUnit of Vascular and Endovascular Surgery, Hospital S. M. Misericordia, Loc. S. Andrea delle Fratte, Perugia, Italy

^lClinical and Interventional Angiology, Swiss Cardiovascular Centre, University Hospital Berne, Berne, Switzerland

^mDepartment of Cardiovascular Surgery, Swiss Cardiovascular Centre, University Hospital Berne, Berne, Switzerland

ⁿDepartment of Vascular Surgery, University Medical Center Utrecht, Utrecht, The Netherlands

^oDepartment of Nephrology & Hypertension, University Medical Center Utrecht, Utrecht, The Netherlands

^pAcademic Section of Vascular Surgery, Imperial College School of Medicine, Charing Cross Hospital, London, United Kingdom

KEYWORDS

Diabetic foot;
Ischaemia;
Neuroischaemia;
Vascular impairment;
Ulcer healing;
Revascularisation

Abstract Ulcerated diabetic foot is a complex problem. Ischaemia, neuropathy and infection are the three pathological components that lead to diabetic foot complications, and they frequently occur together as an aetiologic triad. Neuropathy and ischaemia are the initiating factors, most often together as neuroischaemia, whereas infection is mostly a consequence. The role of peripheral arterial disease in diabetic foot has long been underestimated as typical ischaemic symptoms are less frequent in diabetics with ischaemia than in non-diabetics. Furthermore, the healing of a neuroischaemic ulcer is hampered by microvascular dysfunction. Therefore, the threshold for revascularising neuroischaemic ulcers should be lower than that for purely ischaemic ulcers. Previous guidelines have largely ignored these specific demands related to ulcerated neuroischaemic diabetic feet. Any diabetic foot ulcer should always be considered to have vascular impairment unless otherwise proven. Early referral, non-invasive vascular testing, imaging and intervention are crucial to improve diabetic foot ulcer healing and to prevent amputation. Timing is essential, as the window of opportunity to heal the ulcer and save the leg is easily missed.

This chapter underlines the paucity of data on the best way to diagnose and treat these diabetic patients. Most of the studies dealing with neuroischaemic diabetic feet are not comparable in terms of patient populations, interventions or outcome. Therefore, there is an urgent need for a paradigm shift in diabetic foot care; that is, a new approach

* Corresponding author. Mauri Lepäntalo, Department of Vascular Surgery, Helsinki University Central Hospital, P.O. Box 440, 00029 HUS, Finland. Mobile: +358 50 4271282. E-mail address: mauri.lepantalo@hus.fi (M. Lepäntalo)

and classification of diabetics with vascular impairment in regard to clinical practice and research. A multidisciplinary approach needs to be implemented systematically with a vascular surgeon as an integrated member. New strategies must be developed and implemented for diabetic foot patients with vascular impairment, to improve healing, to speed up healing rate and to avoid amputation, irrespective of the intervention technology chosen. Focused studies on the value of predictive tests, new treatment modalities as well as selective and targeted strategies are needed. As specific data on ulcerated neuroischaemic diabetic feet are scarce, recommendations are often of low grade.

© 2011 European Society for Vascular Surgery. Published by Elsevier Ltd. All rights reserved.

1. Introduction

Diabetic foot ulcers are a major healthcare problem. In 2011, 350 million people worldwide (6.6% of the population) and more than 55 million in Europe suffer from diabetes mellitus,¹ and estimates for 2025 cite a total of over 65 million patients.¹ Complications of foot ulcers are the leading cause of hospitalisation and amputation in diabetic patients. Indeed, 20–40% of the healthcare resources spent on diabetes are related to diabetic feet.^{2,3}

Individuals suffering from diabetes and neuropathy with no other confounders will develop an ulcer in 7–10% of the cases annually, whereas the rate for patients with additional risk factors – such as peripheral arterial disease (PAD), foot deformity, previous ulcers or previous amputation – is 25–30%.²⁻⁴

Major amputation will be needed within 1 year in 5–8% of patients with diabetic ulcers.⁵⁻⁷ Of all amputations on diabetic patients, 85% are preceded by a foot ulcer which subsequently deteriorates to a severe infection or gangrene.²⁻⁴ Diabetes increases the risk of amputation 8-fold in patients aged >45 years,⁸ 12-fold in patients aged >65 years and 23-fold in those aged 65–74 years.⁹

2. Neuropathy

Ischaemia, neuropathy and infection are the three pathological components that lead to diabetic foot complications, and they frequently occur together as an aetiologic triad.¹⁰ Neuropathy and ischaemia are the initiating factors, with a different weight in different patients (Fig. 1), and infection is mostly a consequence.¹¹

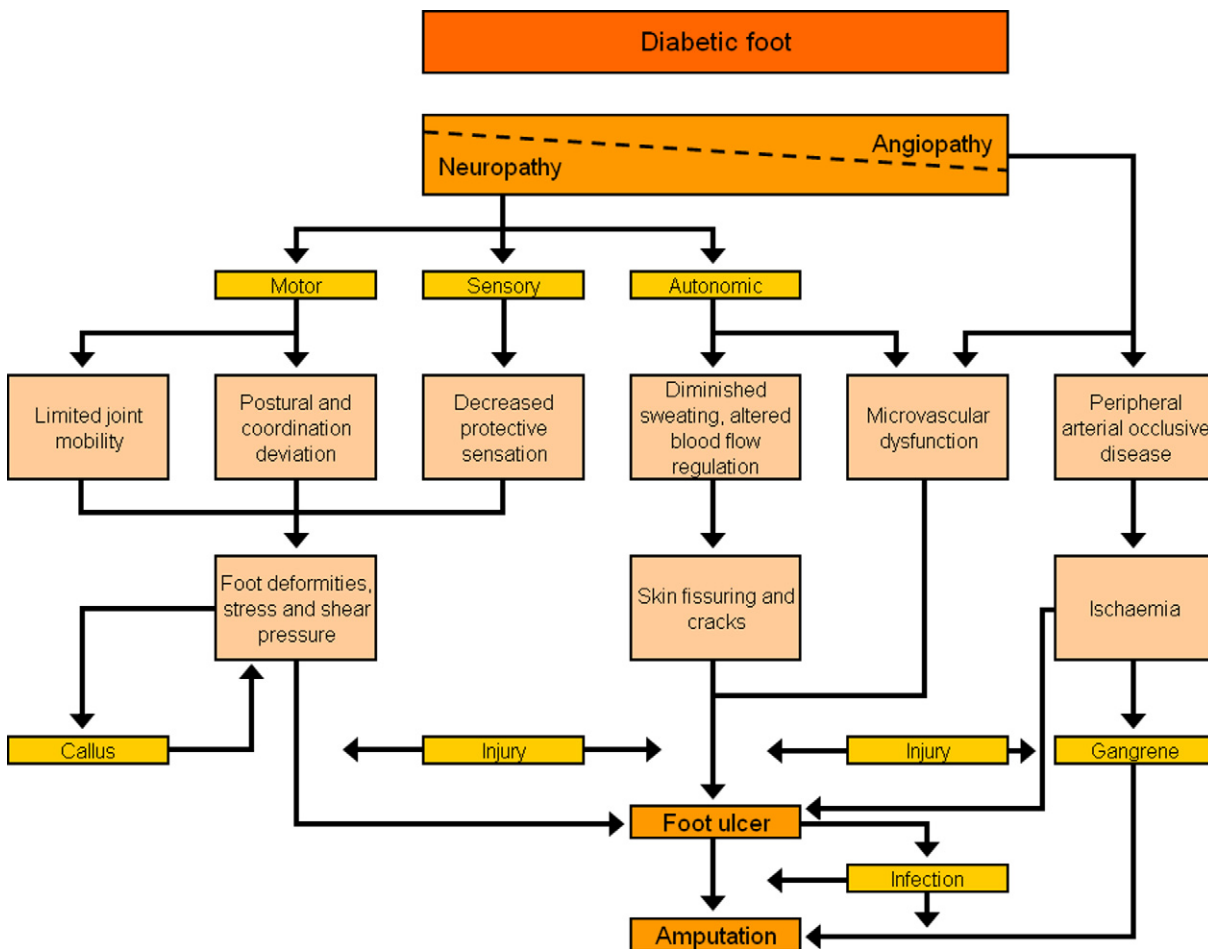


Fig. 1. Pathway to diabetic ulcer. Modified from the International Working Group on the Diabetic Foot, International Consensus on the Diabetic Foot, 1999, with permission.

Due to the lack of protective sensation, the foot is vulnerable to unattended minor injuries caused by excess pressure, mechanical or thermal injury. Motor neuropathy alters the biomechanics and, gradually, the foot anatomy. Foot deformities, limited joint mobility and altered loading of the foot are obvious consequences from these disarrangements. The most important feature of the treatment of any ulcer with neuropathy is to restrict weight bearing, irrespective of the presence of ischaemia.

The treatment of purely neuropathic ulcers is beyond the scope of these guidelines, and neuropathy is further dealt with only in conjunction to ischaemia – i.e. as neuroischaemic ulcers. For the purposes of this chapter, the term diabetic foot refers to an ulcerated diabetic foot with vascular impairment.

3. Ischaemia and neuroischaemia of the diabetic foot

3.1. Underestimation of the role of ischaemia

Poor glucose control accelerates the manifestation of PAD. For every 1% increase in haemoglobin A1c (HbA1c), there is a corresponding increase of 25–28% in the relative risk of PAD.¹² Diabetes increases the prevalence of symptomatic PAD 3.5-fold in men and 8.6-fold in women.¹³ Recent large European cohort studies of individuals with diabetes and foot ulcers confirm that at least half are of neuroischaemic or ischaemic origin.^{14–16} Yet the strategy of prevention and treatment of the diabetic foot has predominantly been focused on neuropathy and its consequences,^{2,17} although ischaemia is the most important factor preventing healing.¹¹ PAD in diabetics is often multisegmental, typically infrapopliteal and poorly collateralised.^{18–20} Ischaemia has been reported to be at least a contributing factor in 90% in diabetics undergoing major amputation.²¹

Recommendation

Ischaemia should not be excluded as a cause of a diabetic foot ulcer unless proven absent.^{22,23} **(Level 5; Grade D)**

3.2. Inadequate understanding of neuroischaemia

Neuroischaemia is the combined effect of diabetic neuropathy and ischaemia, impairing the oxygen delivery to meet metabolic tissue demands in a synergetic way. Macrovascular disease and microvascular dysfunction both impair perfusion in a diabetic foot.²⁴ Peripheral autonomic neuropathy, or auto-sympathectomy, causes deficient sweating and altered blood flow regulation with an opening of arteriovenous shunts and precapillary sphincter malfunction, which decreases nutritive blood flow and manifests as warm, dry skin, increasing the likelihood of skin breakdown.²⁵

The microvascular dysfunction is further characterised by the subsequent capillary leakage and venous pooling as well as hormonal activity in the vessel and inflammation in the wall, all indicating that decreased perfusion in the diabetic foot is more complex and not only related to PAD.^{26–28} Yet PAD is the most important cause of vascular impairment of diabetic foot.²⁴

Recommendation

In neuroischaemic legs, healing is primarily affected by the severity of ischaemia.¹¹ Therefore, from a practical point of view, neuroischaemic and ischaemic lesions should be considered together as both may require revascularisation. **(Level 2b; Grade C)**

3.3. Assessment of vascular impairment beyond ischaemia

The use of rigid non-invasive methods is mostly based on the haemodynamic changes in the macrovascular arterial tree, and criteria applicable to non-diabetic legs are not good enough to predict the healing of diabetic foot lesions.²³ There is a clear need to recognise decreased perfusion or vascular impairment as an indicator for the need for revascularisation in the diabetic foot in order to achieve and maintain healing and to avoid or delay a future amputation.^{4,6,16,23,29–31}

Recommendation

The International Working Group for the Diabetic Foot recommends further vascular studies in case the ulcer has not healed with proper treatment in 6 weeks even if initial diagnostics have suggested only questionable or mild disease.²² **(Level 5; Grade D)**

Critical issue

Criteria for impaired perfusion should be established.

3.4. Delay in revascularisation

As less than 25% of diabetics with PAD report intermittent claudication, and rest pain is far less common than in non-diabetics, the diagnosis of ischaemia is often delayed.² The obvious consequence has been that a vascular consultation is arranged too late for diabetics. Indeed, 30–50% of their foot ulcers are already gangrenous, and, therefore, vascular surgeons are too often not consulted at all.^{2,4}

Recommendation

To prevent a delay in vascular consultation and revascularisation, early non-invasive vascular evaluation is important in identifying patients with poor ulcer healing and a high risk for amputation.^{2,4,6,17,29–31} **(Level 2b; Grade B)**

3.5. Ischaemia, infection and tissue damage

Neuroischaemic ulcers are susceptible to infection. Infection is seldom the direct cause of an ulcer but strongly related to the probability of amputation, especially in combination with ischaemia (PAD).¹¹ Deep infections are manifested either as osteomyelitis or a soft tissue infection spreading along the tendons in the compromised foot. A deep infection is a limb-threatening condition and the immediate cause of amputation in 25–50% of diabetic patients.^{2,4,32–34} In several studies, the outcome of deep foot infection has been related to the extent of tissue involved, comorbidity and co-existing PAD.^{2,4,14,16}

Recommendation

The combination of ischaemia and infection always necessitates urgent treatment, as “time is tissue”.²² (Level 2c; Grade C)

4. Clinical examination from the vascular perspective

4.1. History

4.1.1. General

The primary evaluation with regard to the diabetic foot should include information on the presence of concomitant diseases and their medications; cardiovascular risk factors; occupation and hobbies; lifestyle; smoking as well as the use of alcohol, drugs and other intoxicants; in addition to diabetes-related complications, especially nephropathy, retinopathy and neuropathy. Special attention should also be paid to impaired vision, renal replacement therapy, previous foot education, social isolation and poor access to healthcare.²

4.1.2. Foot-specific history

The main aim of the examination of a diabetic foot is to assess the risk factors for foot ulceration and, in case there already is an ulcer, to evaluate its specific aetiology and duration to allow targeted treatment.^{17,25}

4.2. Inspection

A clinical examination of the foot of a diabetic patient should be performed at least once a year and more frequently in the presence of risk factors. The role of a regular inspection of the diabetic foot cannot be emphasised enough.^{3,11,35} As Andrew Boulton has put it, “For one mistake made for not knowing, ten mistakes are made for not looking.” A neuropathic foot frequently has a characteristic appearance upon inspection.¹⁰

4.3. Vascular clinical examination

Pulse palpation is the cornerstone of vascular examination although it is not necessarily a method of good reproducibility.³⁶ Therefore, clinically significant arterial disease can most often be ruled out only if both dorsalis pedis and posterior tibial pulses are palpable with certainty. Yet, in diabetics even this may not suffice to exclude impaired perfusion.³⁷ Furthermore, the arteria dorsalis pedis pulse is missing in 8% and tibialis posterior pulse in 3% of healthy individuals.³⁸

An ischaemic foot may appear pink and relatively warm even with impaired perfusion due to arteriovenous shunting. Delayed discolouration (rubor) or venous refilling >5s on dependency may indicate poor arterial perfusion.³⁹ Slow capillary refilling time has little diagnostic value.³⁹

Recommendation

Every foot ulcer should be examined for the presence of ischaemia.² (Level 5; Grade 4)

4.4. Neurological clinical examination

Sensory loss tested by pressure perception with a 10-gram (5.07) Semmes–Weinstein monofilament is the most important single test.^{2,17} Vibration perception using a 128 Hz-tuning fork, pinprick discrimination and tactile sensation testing with cotton wool on the dorsum of the foot, as well as testing Achilles tendon reflexes, belong to the neurological examination in addition to looking for foot deformities or bony prominences.²

Recommendation

Every foot ulcer should be examined for the presence of neuropathy.² (Level 5; Grade 4)

4.5. Ulcers

The diabetic foot ulcer is not a disease of the skin but a sign of abnormal loading and impaired perfusion. A systematic classification of foot ulcers would be helpful for the comparison of data, but only few scoring systems have been validated.⁴⁰ The most frequently used systems include perfusion, the extent and size of tissue involvement as well as infection.^{29,41}

Critical issue

The validity of scoring systems needs to be evaluated specifically in ischaemic diabetic ulcers.

4.6. Infection

Ulcer infections are diagnosed clinically on the basis of local signs and symptoms of inflammation. These include purulent secretion in the ulcer or at least two of the following signs or symptoms: redness, warmth, swelling, pain, delayed improvement or bad odour. The clinical signs of infection can be reduced due to diminished leucocyte function, PAD, poor metabolic control and neuropathy.⁴² Occasional systemic signs are fever and poor general condition.^{34,43} In almost 50% of patients with diabetes and deep foot infections, signs such as increased white blood cell count, erythrocyte sedimentation rate, C-reactive protein concentration and fever have been found absent, resulting in a delay in diagnosis.^{32–34} Some patients with a diabetic foot infection also have a worsening in their glycaemic control. A swollen foot with a long-lasting ulceration or a red swollen digit should always arouse suspicion of an infection extending to deep tissue. The most common sign of a diabetic foot infection with an ulcer is increased exudation rate.^{32,44} Unroofing a superficial eschar may reveal deeper abscesses.¹⁰ Indeed, the severity of infection should be assessed after debridement, based on its extent and depth as well as the presence of any systemic findings.²² Tissue specimens should be obtained by biopsy, curettage or aspiration, preferable to wound swab specimens, prior to starting empirical antibiotic therapy.^{45–47}

A continuous extension of a soft tissue infection to the underlying bone poses both diagnostic and therapeutic challenges.^{32–34,48} Imaging studies may help detect pathological findings in the bone.⁴⁹ Plain radiographs of the foot may be of value in revealing the presence of a foreign body, gas, osteolysis or joint effusion. Radiological diagnosis is often

difficult because changes suggesting osteomyelitis usually take several weeks to become visible on X-ray.

Fever as well as an increased erythrocyte sedimentation rate (ESR), white cell count and C-reactive protein concentrations (CRP) are usually helpful in recognising soft tissue infections or abscess. An MRI, bone scan or CT scan can be of value in evaluating the presence and extent of a deep foot infection.

Recommendation

Every diabetic foot ulcer should be examined for the presence of infection.² (Level 5; Grade D)

4.7. Non-invasive vascular studies – special considerations related to the diabetic foot

In the case of any uncertainty as to foot perfusion, the measurement of ankle pressure, the ankle-brachial systolic pressure index (ABI) and toe pressures should be included. Normal ABI values range between 0.9 and 1.3, as high values suggest non-compressible arteries (pseudohypertension) characteristic of advanced mediasclerosis, which is typical in diabetes. Less severe calcification may result in a normal ABI despite clinically significant PAD.⁵⁰ In a series of 554 diabetics with vascular impairment, ankle pressures could not be measured in 35% of the patients.⁵¹ An ABI <0.4–0.45, absolute systolic ankle pressure <55 mmHg and toe pressure <30 mmHg have most frequently been used to indicate the need for revascularisation.^{10,52,53} Pseudohypertension may be revealed by pulse volume recording (PVR),⁵⁴ but there are not enough data to support the use of methods such as the pole test.⁵⁵ In hand-held Doppler examination, an absent or monophasic flow velocity signal from a foot artery indicates occlusion or collateral flow.

Recommendation

Trust ABI when low but not when high. An ABI <0.6 indicates significant ischaemia in respect to wound healing potential, whereas an ABI >0.6 has little predictive value and, therefore, at least the toe pressure should be measured.²² (Level 5; Grade D)

Toe pressure may give more reliable information on the level of distal flow capacity but, as reported in one study, it could not be measured in 16% of cases due to a previous amputation or gangrene of the big toe.⁵¹ Vascular intervention has been suggested feasible for diabetics with an ulcer as well as ankle pressures <80 mmHg⁵⁴ and toe pressure <55 mmHg.⁵⁶ The probability of ulcer healing is clearly related to available perfusion pressures and, regardless of the method used, follows a sigmoid curve (Fig. 2).¹⁷

Recommendation

An ulceration of the foot in diabetes will generally heal if the toe pressure is >55 mmHg, whereas healing is usually severely impaired when toe pressure is <30 mmHg.²² (Level 2b; Grade B)

Transcutaneous oxygen pressure (TcPO₂) <30 mmHg has been considered to predict that the infection will not

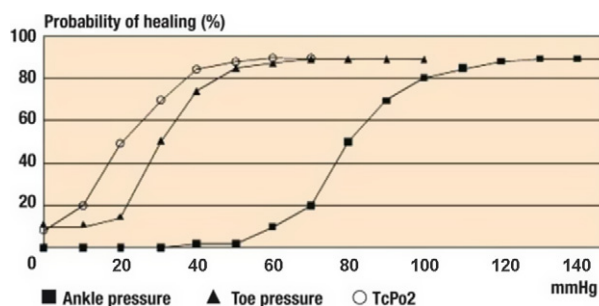


Fig. 2. Probability of ulcer healing as related to different levels of systolic ankle pressure, toe pressure and TcPO₂. From the International Consensus on the Diabetic Foot, 1999, with permission.

resolve itself and the ulcer will not heal.⁵² The accuracy of these measurements in patients with critical leg ischaemia has been questioned, especially in the presence of tissue oedema.^{53,57} Nevertheless, TcPO₂ may be a useful method of identifying tissue lesions that may heal with conservative treatment.^{58,59} TcPO₂-values >40 mmHg support conservative treatment alone as the first approach as >90% of the ulcers healed.^{59,60}

Recommendation

Ulceration of the foot in diabetes will generally heal if the TcPO₂ is >50 mmHg. Healing is usually severely impaired when TcPO₂ is <30 mmHg.²² (Level 2b; Grade B)

Low ABI, ankle pressure, toe pressure and TcPO₂ suggest that a diabetic ulcer may not heal, but the limitations of each technique should always be considered.

4.8. Vascular imaging – special considerations related to the diabetic foot

Extensive calcification of the infrapopliteal arterial tree may prevent proper duplex diagnostics as well as computed tomography angiography, although the use of multisliced devices decreases interpretation difficulties caused by arterial wall calcifications.^{61–64} MRA may have limited spatial resolution and the images may be distorted by previous stents, implants and flow disturbances. The use of the paramagnetic contrast material gadolinium has been reported to cause nephrogenic systemic fibrosis typically in patients with renal failure.^{65–67}

Recommendation

Any of the techniques are useful for mere imaging as the accuracies of the different techniques in diagnosing stenosis of >50% in the infrapopliteal segment are acceptable and similar when using DSA as the reference.⁶¹ (Level 2b; Grade B)

A systematic angiographic classification of infrapopliteal occlusive lesions would be valuable in order to have comparable data for future comparisons of different revascularisation techniques. At present, at least three classifications are in use,^{19,23,68} each with different degrees of validation and inter-observer agreement.^{19,69–71} None of them has gained larger acceptance in the practice of assessing angiographic patterns of ulcerated diabetic feet.

Chronic renal failure is increasingly common in diabetics with a foot ulcer. Metformin treatment should be discontinued before angiography as it may cause lactic acidosis.⁷² Renal insufficiency influences the choice of imaging method, because contrast media are nephrotoxic agents. In the case of mild chronic renal failure, regular DSA and CTA can be performed, but intravenous hydration of the patient is recommended before and after the examination.^{72,73} In more severe cases, selective angiography with a minimal amount of contrast media, preferably diluted non-ionic iso-osmolar, can produce excellent imaging when focused on the target lesion.⁷³ Alternatively, duplex ultrasound can be used for imaging and sometimes also for guiding the endovascular procedure.⁷⁴

Recommendation

Detailed visualisation of infrapopliteal arteries, including the arteries of the foot, is necessary for a complete evaluation of diabetic patients.²² (Level 5; Grade D)

Critical issue

The risks of gadolinium-enhanced MRA for imaging diabetic patients with kidney failure should be considered and further evaluated.

5. Treatment of ulcerated neuroischaemic diabetic feet

5.1. Multifactorial approach mandatory

The complexity of diabetic foot ulcers necessitates in-depth knowledge of the underlying pathophysiology and a multifactorial approach in which aggressive management of ischaemia and infection is of major importance (Table 1).

Recommendation

Patients in need of revascularisation to improve perfusion and achieve healing should be identified by an extensive clinical examination and non-invasive, vascular testing.^{22,23} (Level 5; Grade D)

Metabolic control also plays an important role in comprehensive treatment. Blood glucose control may be difficult because of infection. If the patient is on oral antidiabetic drugs, a temporary switch to insulin may be necessary. On the other hand, high blood glucose worsens infection and is associated with poorer operative results, morbidity and mortality. The recommended target level of HbA1c should be <7.0–7.5% but higher if hypoglycaemic episodes are a problem, and the LDL level should be <1.8mmol/L and blood pressure <130/80mmHg, while less stringent goals should be accepted for elderly and multimorbid patients.⁷⁵

Recommendation

Intensive management of diabetes, including glycaemic and platelet aggregation control, treatment of hypertension and dyslipidaemia as well as non-pharmacological interventions, decreases vascular complications in the long run.⁷⁶ (Level 1a; Grade A)

5.2. Management of infection

Antibiotic therapy is necessary for virtually all infected wounds, but it is not beneficial for non-infected ulcers and is insufficient without appropriate wound care. In long-standing ulcers or ulcers with delayed healing and ischaemia or necrotic tissue, polymicrobial flora with an unknown causative agent is frequently present. Broad-spectrum empirical therapy is not routinely required but is indicated for moderate to severe infections.^{34,77} Antibiotic therapy is continued until there is evidence that the infection has been resolved but not necessarily until the wound has healed.⁴⁹

Patients with uncontrolled or limb-threatening infections require immediate hospitalisation, immobilisation and intravenous antibiotics. Infections accompanied by a deep abscess, extensive bone or joint involvement, crepitus, substantial necrosis or gangrene, or necrotising fasciitis, need prompt surgical intervention. Infections can spread extremely rapidly in a diabetic foot, which may lead to a life-threatening general septic infection if treatment is delayed. Urgent evaluation of lower limb circulation, treatment of infections and surgical procedures, including debridement and revascularisations, are often needed as first-line leg salvage strategies.^{48,50,78}

Recommendation

Surgical intervention for moderate or severe infections is likely to decrease the risk of major amputation.²² (Level 2c; Grade B)

5.3. Infringuinal revascularisation

The crucial issue is to decide whether revascularisation is needed for a certain lesion in a certain patient.¹⁰ Although non-invasive evaluation is helpful, the decision to intervene is made according to the symptoms and clinical findings.¹⁰ Anatomical imaging should be considered only as strategic.⁷³

If both an endovascular and a bypass procedure are possible with an equal outcome to be expected, endovascular treatments should be preferred.⁷⁹ Especially patients with chronic neuroischaemic ulcers, borderline toe pressures and short lesions are candidates for endovascular treatment. However, continuous surveillance and a low threshold for secondary imaging, percutaneous transluminal angioplasty (PTA) or bypass are basic principles when treating diabetic ulcers with an endovascular procedure.⁸⁰ Bypass grafting is to be used for long occlusions. Patency rates after crural and pedal bypasses are similar in diabetics and non-diabetics.⁸¹ (For femoropopliteal reconstructions, see Chapter IV, Treatment of Critical Limb Ischaemia, pp. S43–S59.)

5.4. Infrapopliteal endovascular procedures

Endovascular therapy for infrapopliteal arterial disease is gaining acceptance as a first-line revascularisation method to improve ulcer healing and limb salvage.⁷⁹ The angioplasty of isolated crural arterial lesions in diabetic patients with an unhealed ulcer is also considered an effective and safe therapeutic modality to avoid limb loss.⁸² There are several studies showing good results and patency rates after endovascular treatment of PAD with critical ischaemia.^{82–86} An important task for any revascularisation is to achieve

Table 1 Multifactorial treatment of a diabetic foot ulcer

Goal	Treatment
Improvement of perfusion	Endovascular revascularisation (PTA)
	Reconstructive vascular surgery (bypass)
	Vascular drugs
	Reduction of oedema
	Hyperbaric oxygen
Treatment of infection	Antibiotics (oral or parenteral)
	Incision, drainage
	Resection
Reduction of oedema	External compression therapy
	Intermittent compression (pumps)
	Diuretics
Pain control	Analgesic drugs (local or systemic)
	Immobilisation, offloading, relief of anxiety and fear, TNS
Improvement of metabolic control	Insulin treatment
	Necessary nutritional support
Offloading	Protective and therapeutic footwear
	Insoles, orthosis
	Total contact cast, walkers
	Crutches, wheelchair, bed rest
Wound bed preparation	Debridement, removal of debris
	Topical treatment, dressings
	Control of exudation, moist wound healing, GCSF infection control, NPWT
	Tissue engineering, growth factors, matrix modulation
Removal of dead tissue	Incision, drainage, amputation
Correction of foot deformities	Corrective foot surgery, skin transplant, amputation
Improvement of general condition	Fluid and nutrition replacement therapy
	Aggressive treatment of concomitant disease, antiplatelet drugs, antihypertensive agents, lipid decreasing agents
	Cessation of smoking
	Physiotherapy
Implementation of systematic care	Patient and staff education
	Support and follow-up
	Multidisciplinary coordination, communication, staggered treatment chains
	Improvement of concordance process oriented approach

GCSF, granulocyte colony-stimulating factor; NPWT, negative-pressure wound therapy; PTA, percutaneous transluminal angioplasty; TNS, total neuropathy score.

at least one open infrapopliteal artery down to the foot, preferably the artery that supplies the anatomical region of the ulcer.⁸⁰ The revascularisation of the plantar arch and branches of the peroneal artery has been suggested recently.⁸⁷⁻⁸⁹ The role of revascularisation of the specific angiosome feeding the ulcer area has not been settled.⁹⁰⁻⁹³

5.5. Distal bypass procedures

If proximal vessels are free of major wall changes, inflow to the graft can be taken from the superficial femoral or popliteal artery. Distal outflow vessels in diabetics are often heavily calcified, making the distal anastomosis challenging.

Clamping of vessels should be avoided to prevent any lesions distal to the anastomosis. In such cases, gentle obstruction balloons or tourniquet ischaemia provide better visibility while the anastomosis is performed.⁹⁴

The best graft material in distal bypasses is an autogenous vein as it has better patency and resistance to infection than a prosthetic graft. In a retrospective study, the Boston Deaconess Hospital Group reported results from 1032 limb salvage bypasses on the dorsalis pedis artery in 865 patients, mostly diabetics.⁹⁵ The patency of saphenous vein grafts was better than all other conduits, with a secondary patency rate of 67.6% vs. 46.3% at 5 years.⁹⁵

5.6. Immediate outcome after revascularisation

Several conditions, such as chronic renal failure requiring long-term dialysis, an arterial graft of poor quality or severe foot infection may indicate problems in leg salvage.⁹⁶ Diabetes along with coronary artery disease, foot gangrene and an urgent operation have been found to be independent predictors of 30-day post-operative mortality and/or major lower limb amputation after revascularisation for CLI.⁹⁶ Systemic complications are encountered in approximately 10% of patients.⁹⁷

5.7. Endovascular intervention or surgical bypass

There is not a single randomised controlled trial available comparing endovascular and surgical revascularisation in the treatment of impaired perfusion or critical ischaemia in diabetics.^{97,98} A literature search revealed only seven case series on revascularisations exclusively for diabetic feet, provided that all patients were diabetics, had an ulcer and were treated with an infrainguinal revascularisation (Table 2).

As the infrapopliteal region is strongly affected by diabetic PAD, current interest is increasingly targeted on infrapopliteal revascularisations. New endovascular techniques are rapidly evolving, despite the lack of RCTs comparing open and endovascular revascularisations below the knee. However, a recent meta-analysis is available for both infrapopliteal surgery and infrapopliteal endovascular interventions,^{106,107} with 29 and 30 studies included, respectively. As 88% of the patients were diabetics and 88% had tissue loss in the bypass group with 2320 grafts studied, the results may be accepted to be indicative of a diabetic population. Unfortunately, only 61% of the patients in the endovascular group were diabetics and only 76% of them suffered from tissue loss, and the group therefore rather represented a mixed group. No distal pressure data were available. Primary and secondary mid-term patency rates were better after bypass, but there was no difference in limb salvage. The so-called patency/leg-salvage gap seemed wider in the endovascular than in the surgical series – i.e. occlusion of the revascularised segment was less likely to lead to amputation after an endovascular procedure than surgical bypass. It is unclear whether bypass patients had more severe ischaemia pre-operatively or whether open surgery caused more leg morbidity. As the BASIL trial showed, only 29% of patients are suitable for both treatment methods, and patient populations are thus bound to be different in endovascular and surgical series.¹⁰⁸ Bypass surgery and endovascular interventions are therefore complementary techniques for revascularisation in diabetic patients with non-healing ulcers.⁵⁶ Indeed, an analysis of infrapopliteal revascularisations in 611 diabetics with 417 open and 194 endovascular revascularisations showed a comparable outcome in terms of amputation-free survival.⁷⁹

Recommendation

The choice between different methods of revascularisation – open, endovascular or hybrid – depends on comorbidity, severity and extension of the arterial lesions as well as the expertise of the centre. **(Level 2c; Grade B)**

5.8. Microvascular flaps

Microvascular free flaps may be used to cover large tissue defects and ulcers overtaking tendons and bones in diabetic feet. In a recent review there were 17 case series, the largest with 79 patients, 85% of whom were diabetics and 66% of whom underwent a procedure combining revascularisation and free flap transfer.¹⁰⁹ Revascularisations of ischaemic diabetic feet combined with free flap transfer represent only a small fraction – 4% at most – of all interventions to improve diabetic foot perfusion.¹¹⁰

Recommendation

When ischaemia coincides with a large diabetic foot defect, major amputation may be prevented in an ambulatory patient by combining revascularisation with microvascular flap transfer.¹⁰⁹ **(Level 4; Grade C)**

5.9. Timing of the treatment of infection vs. revascularisation

The most important step in controlling deep infection is urgent incision and drainage of an abscess as well as radical debridement of all infected, nonviable necrotic tissue.³²⁻³⁴ The debridement should be done first and revascularisation thereafter.^{32-34,48} Distal bypass, when needed, is usually delayed 2–5 days to control the infection.^{94,111,112} Simultaneous revascularisation, preferably endovascularly, in patients without systemic sepsis allows maximising blood flow at the initial debridement. Those having a minor amputation before bypass have been reported to fare worse than those who were revascularised first.¹¹³ Common sense is essential in this setting since purulent lesions necessitate an amputation first whereas mummified gangrene allows revascularisation first.

In situations with no limb-threatening infection, the blood supply to the wound/extremity should be optimised before surgical debridement to ensure that potentially viable tissue is not unnecessarily removed. This may take weeks.

Recommendation

The severity of infection guides the decision whether to debride, to revascularise or to use a simultaneous approach first. **(Level 2c; Grade C)**

5.10. Debridement

Debridement after the damage control phase has been studied extensively. A large review comprising surgical debridement, surgical excision, the use of hyperbaric oxygen, negative-pressure wound therapy, skin grafting, bioactive local therapy products as well as electrical, magnetic, ultrasound and laser therapies¹¹⁴ showed no evidence to prove that one method was better than the others with regard to the probability of healing according to Cochrane Database.¹¹⁴⁻¹¹⁶

Recommendation

No single method is outstanding in terms of enhancing diabetic ulcer healing. **(Level 1c; Grade A)**

Table 2 Case series including exclusively infrainguinal revascularisations for ischaemic ulcerated diabetic feet

Author	Patients; N/gender/ age (mean/median)	Comorbidity	Intervention	Infra- popliteal distribution	30-day complications	Follow-up (fu)	Outcome
Rosenblum, 1994 ⁹⁹	39/M33, F6/62.3 yrs	NA	Infrapopliteal bypass grafts	79%	Major amputation 3%, mortality NA	21.2 months (mean), range 2–64	83% primary ulcer healing with graft patency during fu
Wölfle, 2000 ¹⁰⁰	125/NA/70 yrs	CAD 57%, ESRD 25%	Infrapopliteal bypass grafts	100%	Major amputation NA, mortality 2%	24 months (mean)	Leg salvage 80% and patency 76% at 1 yr, mortality 51% during fu
Schneider, 2001 ¹⁰¹	84/NA/68 yrs	CAD 48%, ESRD 42%	Infrapopliteal PTA (mostly stenoses)	100%	Major amputation NA, mortality 6%	24 months (mean)	Leg salvage 82% at 1 yr, mortality 35% during fu
Schneider, 2001 ¹⁰¹	110/M67, F43/69 yrs	CAD 43%, ESRD 69%	Revascularisation using either fem-distal bypass, combined SFA PTA and distal bypass grafting or short distal bypass graft	100%	NA	23 months (mean)	Leg salvage 89%, patency 78% at 2 yrs, mortality NA
Faglia, 2002 ¹⁰²	219/NA/NA	CAD 55%, ESRD 4%	Femorodistal and infrapopliteal PTA (of stenoses >50%)	94%	Major amputation 5%, mortality 0%	12 months (median), range 5–30	Leg salvage NA, mortality 5.3% at 1 yr
Dorweiler, 2002 ¹⁰³	46/M36, F10/69 yrs	CAD 46%, ESRD 13%	Pedal bypass grafts	100%	Major amputation 7%, mortality 2%	28 months (median), range 1–70	Leg salvage 87% at 2 yrs
Bargellini, 2008 ¹⁰⁴	60/M41, F19/69.4 yrs	CAD 42%, CVD 25%	Multi-level subintimal PTA in patients unfit for surgery	43%	Major amputation 5%, mortality 5%	23 months (mean), range 0–48	Leg salvage 93.3%, mortality 10% at 1yr
Ferraresi, 2009 ¹⁰⁵	101/M85, F16/66 yrs	CAD 28%, ESRD 3%	Infrapopliteal PTA	100%	NA	35 months (mean)	Leg salvage 93%, mortality 9% during fu

As to hyperbaric oxygen therapy, a recent double-blind RCT demonstrated a significantly improved outcome in the intervention group as the treated patients were more likely to heal within 12 months: 25/48 (52%) vs. 12/42 (27%); $p=0.03$.¹¹⁷ Notably, a favourable outcome seems to be connected to moderate rather than severe ischaemia.¹¹⁷⁻¹¹⁹ A recent systematic review by the NICE Guidelines Development Group in the UK concluded that the available data were insufficient to demonstrate that the intervention was cost-effective.¹²⁰

Recommendation

Hyperbaric oxygen therapy may be indicated for a selected group of diabetic ulcers, but it is not clear which patients are likely to benefit and what is the optimal duration. **(Level 1b; Grade A)**

Negative-pressure wound therapy (NPWT) is used to accelerate healing and to ease local wound therapy. The prerequisite for optimal effect is that there is sufficient blood supply for ulcer healing. Armstrong et al. used a $TcPO_2 \geq 50$ mmHg or toe pressure ≥ 30 mmHg as inclusion criteria in their large multicentre trial.⁵⁸ NPWT does not replace surgical wound debridement and measures to improve blood circulation. There must be no significant infection or gangrene in the wound when NPWT is initiated.

Recommendation

Negative-pressure wound therapy appears to be as effective and, under certain circumstances, more effective than other available local wound treatments in patients without significant infection.^{121,122} **(Level 1a; Grade A)**

5.11. Foot surgery and correction of deformities

There are surgical techniques to offload non-infected ulcers, including surgical excision, arthroplasties, metatarsal head resections and Achilles tendon lengthening. These procedures seem to expedite healing and reduce ulcer recurrence after revascularisation or if tissue perfusion is adequate.¹²³ Elective surgery should be considered to correct structural deformities that cannot be accommodated by therapeutic footwear.

Recommendation

Foot surgery to offload pressure areas may be beneficial to prevent ulcer recurrence after revascularisation for neuroischaemic diabetic foot ulcers. **(Level 4; Grade 5)**

5.12. Minor amputation and removal of necrotic tissue

Minor amputations can be performed under ankle blockade. Minor amputations should be left open whenever skin viability is compromised. Patients with restricted acral gangrene or dry lesions usually benefit from revascularisation first. Patients frequently need several debridements and care lasting several months before ulcers have healed even after successful bypass.¹¹¹ Heel ulcers are especially vulnerable as poor perfusion in the heel fat pad and the danger of debriding into the calcaneus may expose the area to deep infection. Once the ulcer bed infection has subsided,

healing per second intention, or covering of the wound should be discussed.

Recommendation

Toe, ray and transmetatarsal amputations are preferred whenever possible as they enable a broader distribution of weight during ambulation.¹⁰ **(Level 4; Grade 5)**

5.13. Amputations

Amputations are urgent or curative.¹²⁴ Indications for an amputation include the removal of infected or gangrenous tissue, controlling infection and creating a functional foot or stump that can accommodate footwear or a prosthesis. The preservation of leg length aids ambulation and decreases energy expenditure. Yet the surgical site should heal primarily. A closed toe and metatarsal amputation typically leave the patient with a functional foot for walking.^{10,125-127}

If the healing of a toe is in doubt, metatarsal amputations should be used liberally after revascularisation. Piecemeal amputations should be avoided. In situations involving extensive tissue loss and precluding a functional foot, as well as when there are non-healing wounds despite patent revascularisation and for controlling sepsis, amputation below the knee is necessary.¹²⁸

Recommendation

Bedridden patients, poor ambulation that is not worsened by amputation, life expectancy less than 1 year, and a non-revascularizable leg are indications for performing a major amputation, even above the knee when necessary. **(Level 4; Grade D)**

6. Outcomes

6.1. Ulcer healing

As an example of the recent positive trend in healing rates, it has been observed that 50–60% of ulcers had healed at 20 weeks of observation and more than 75% had healed at 1 year.¹¹ Yet it is difficult to obtain reliable data on ulcer healing rates in diabetic populations. Furthermore, the definition and observation time may cause problems in the assessment of wound healing. Typically, heel ulcers heal slowly. The completeness of revascularisation seems important as shown by the predictive value of post-procedural $TcPO_2$ measurements by Faglia et al.⁵⁹ Complete tissue healing after infrainguinal bypass, including the healing of ischaemic tissue lesions and surgical wounds, was 26% at 6 months and 63% at 1 year, which was slower than in non-diabetics.¹²⁹ The median time to complete tissue healing was 213 days in diabetics and 159 days in non-diabetics.¹²⁹ In a large study by Apelqvist et al., 801 patients underwent angiography, and 297 were treated medically, 314 by an endovascular technique, and 190 by open surgical revascularisation. Revascularisations improved ulcer healing, whereas the number of ulcers and severity of PAD as well as congestive heart failure and renal function impairment were associated with poor ulcer healing.¹³⁰ Renal failure has been reported to independently predict non-healing of neuroischaemic foot lesions (OR 3.04).⁶

6.2. Leg salvage

Leg salvage is a composite endpoint and only an indirect measure of successful revascularisation – only half of the diabetic patients with CLI were observed to undergo major amputation within 6 months if they were not candidates for revascularisation.¹³¹ Occlusion of all three crural arteries, dialysis, wound infection, multiple ulcers, oedema and non-compliance to treatment increase the risk of major amputation.^{16,51} Leg salvage rates of approximately 80% at 1 year and roughly 70% at 3 years have been reported after revascularisations.⁹⁷ Diabetic patients with end-stage renal disease (ESRD) and gangrene are at high risk of losing their leg despite successful infrapopliteal revascularisation.^{132,133}

Proper patency data on revascularisations for ulcerated diabetic feet are not available as almost all series mix diabetics and non-diabetics as well as different indications and levels of disease.⁹⁷

6.3. Mortality

Diabetic patients with CLI have been observed to have 53% mortality at 6 months if not suitable for revascularisation.¹³¹ ESRD and coronary heart disease increase mortality.^{51,130} Peri-operative mortality in reported revascularisation series tends to be mostly below 5%.⁹⁷ Mortality is roughly 10–20% at 1 year and 40–50% at 5 years after open surgery; long-term data are missing in endovascular series.⁹⁸

6.4. Quality of life

Successful revascularisation for critical ischaemia improves the quality of life for diabetics.^{134,135} Concurrent diseases limit the chances of improving quality of life. Indeed, diabetics with impaired ambulatory status and gangrene at presentation had an 83% probability (OR 10.5) of not benefiting from the intervention, and for those also with end-stage renal disease and prior vascular surgery, the probability of failure was 93% (OR 23.7).¹³⁶

Recommendation

Comorbidities, especially renal failure and impaired ambulatory status, at presentation are major factors for poor outcome in diabetics with ischaemic ulcers. These comorbidities should be taken into consideration when deciding whether or not to revascularise. **(Level 2a; Grade B)**

7. Multidisciplinary team approach

7.1. Multidisciplinary team

Diabetic foot ulcers should be managed by a multidisciplinary team, comprising individuals who can deliver all the necessary and wide-ranging skills: medical and surgical as well as podiatric, nursing and orthotic experts.¹²³ Using a protocol-driven and multidisciplinary approach will lower the number of diabetics suffering from numerous foot complications. Education, presented in a structured and organised manner, also plays an important role in the prevention of foot problems when combined with podiatry

and the use of adequate preventive footwear and offloading techniques.

The associated systemic factors that impair wound healing need to be treated; these include hyperglycaemia, cardiovascular disease, peripheral vascular disease, increased incidence of bacterial infections, and plantar pressure redistribution.¹³⁷ The medical management of ulcers includes offloading, treatment of infection (local, cellulitis, osteomyelitis or sepsis), debridement, wound bed preparation and dressings. Surgery is often needed to revascularise the limb, to treat the infected ulcers and to achieve offloading.

A multidisciplinary approach is supported by the complexity of the disease in patients with diabetic foot ulcers as most of them present with multi-organ disease. Comparative cohort studies with regard to healing and amputations, epidemiological studies on incidence and diabetic-foot-related amputations as well as health economic studies strongly support this approach.

Vascular diagnostics and intervention are an integral part of the strategy but are implemented conservatively, the main reason being a poorly functioning treatment chain with delayed referrals to vascular centres.^{2,17} To improve amputation prevention, this window of opportunity should not be missed.^{4,6,16,29,30} According to the most optimistic view, up to 85% of amputations may be prevented by a multidisciplinary approach.¹⁷

Recommendation

Early referral and intervention are crucial for to improve diabetic foot ulcer healing and to prevent amputation:

- Do non-invasive vascular testing to all individuals with diabetes and a foot ulcer.
- Image if non-invasive tests indicate ischaemia or when mild or questionable ischaemia is diagnosed and conservative treatment (Table 1) does not promote ulcer healing (in 4–8 weeks)
- Revascularise to repair distal perfusion to promote ulcer healing whenever feasible.

(Level 2b; Grade B)

8. Summary

The incidence of diabetes is increasing, and diabetic foot ulcers continue to be a growing challenge for healthcare as well as for vascular services. A neuroischaemic diabetic foot is far more common than is usually thought. From a practical point of view, diabetics with neuroischaemic feet and the small group of diabetics with purely ischaemic ulcerated diabetic feet should be lumped together. A diabetic foot ulcer should always be considered to have vascular impairment unless otherwise proven.

There is a paucity of data on how to diagnose and treat these diabetic patients in the best possible way. Most of the studies dealing with neuroischaemic diabetic feet are not comparable in terms of patient populations, interventions or outcome. Therefore, there is an urgent need for a paradigm shift in diabetic foot care – i.e. a new approach and classification of diabetics with impaired perfusion with regard to clinical practice and research. A multidisciplinary approach needs to be implemented systematically so as to

intervene with a diabetic foot with impaired arterial supply to improve healing and to avoid amputation irrespective of the technique chosen.

Conflict of Interest/Funding

None

References

- 1 www.diabetesatlas.org
- 2 International Working Group on the Diabetic Foot. *International Consensus on the Diabetic Foot and Practical Guidelines on the Management and the Prevention of the Diabetic Foot*. Amsterdam, the Netherlands, 2011. Available on CD-ROM at: www.idf.org/bookshop or www.diabeticfoot.nl.
- 3 Boulton AJ, Vileikyte L, Ragnarson-Tennvall G, Apelqvist J. The global burden of diabetic foot disease. *Lancet* 2005;**366**(9498): 1719–24.
- 4 Apelqvist J, Larsson J. What is the most effective way to reduce incidence of amputation in the diabetic foot? *Diabetes Metab Res Rev* 2000;**16**(Suppl 1):S75–83.
- 5 Apelqvist J, Larsson J, Agardh CD. Long-term prognosis for patients with diabetic ulcers. *J Intern Med* 1993;**233**:485–91.
- 6 Prompers L, Schaper N, Apelqvist J, Edmonds M, Jude E, Mauricio D, et al. Prediction of outcome in individuals with diabetic foot ulcers: focus on the differences between individuals with and without peripheral arterial disease. The EURODIALE Study. *Diabetologia* 2008;**51**(5):747–55.
- 7 Jonasson JM, Ye W, Sparén P, Apelqvist J, Nyrén O, Brismar K. Risks of nontraumatic lower-extremity amputations in patients with type 1 diabetes: a population-based cohort study in Sweden. *Diabetes Care* 2008;**31**:1536–40.
- 8 Johannesson A, Larsson GU, Ramstrand N, Turkiewicz A, Wiréhn AB, Atroschi I. Incidence of lower-limb amputation in the diabetic and nondiabetic general population: a 10-year population-based cohort study of initial unilateral and contralateral amputations and reamputations. *Diabetes Care* 2009;**32**(2):275–80.
- 9 Beckman JA, Creager MA, Libby P. Diabetes and atherosclerosis: epidemiology, pathophysiology, and management. *JAMA* 2002;**287**(19):2570–81.
- 10 Kalish J, Hamdan A. Management of diabetic foot problems. *J Vasc Surg* 2010;**51**(2):476–86.
- 11 Apelqvist J. The foot in perspective. *Diabetes Metab Res Rev* 2008;**24**(Suppl 1):S110–5.
- 12 Selvin E, Marinopoulos S, Berkenblit G, Rami T, Brancati FL, Powe NR, et al. Meta-analysis: glycosylated hemoglobin and CVD disease in diabetes mellitus. *Ann Intern Med* 2004;**21**:421–31.
- 13 Kannel WB, McGee DL. Update on some epidemiologic features of intermittent claudication: the Framingham Study. *J Am Geriatr Soc* 1985;**33**(1):13–8.
- 14 Jeffcoate WJ, Chipchase SY, Ince P, Game FL. Assessing the outcome of the management of diabetic foot ulcers using ulcer-related and person-related measures. *Diabetes Care* 2006;**29**: 1784–7.
- 15 Prompers L, Huijberts M, Apelqvist J, Jude E, Piaggese A, Bakker K, et al. High prevalence of ischaemia, infection and serious comorbidity in patients with diabetic foot disease in Europe. Baseline results from the Eurodiale study. *Diabetologia* 2007;**50**(1):18–25.
- 16 Gershater MA, Löndahl M, Nyberg P, Larsson J, Thörne J, Eneroth M, et al. Complexity of factors related to outcome of neuropathic and neuroischaemic/ischaemic diabetic foot ulcers: a cohort study. *Diabetologia* 2009;**52**(3):398–407.
- 17 Apelqvist J, Bakker K, van Houtum WH, Schaper NC; International Working Group on the Diabetic Foot (IWGDF) Editorial Board. Practical guidelines on the management and prevention of the diabetic foot: based upon the International Consensus on the Diabetic Foot (2007). Prepared by the International Working Group on the Diabetic Foot. *Diabetes Metab Res Rev* 2008;**24**(Suppl 1):S181–7.
- 18 Diehm N, Shang A, Silvestro A, Do DD, Dick F, Schmidli J, et al. Association of cardiovascular risk factors with pattern of lower limb atherosclerosis in 2659 patients undergoing angioplasty. *Eur J Vasc Endovasc Surg* 2006;**31**(1):59–63.
- 19 Graziani L, Silvestro A, Bertone V, Manara E, Andreini R, Sigala A, et al. Vascular involvement in diabetic subjects with ischemic foot ulcer: a new morphologic categorization of disease severity. *Eur J Vasc Endovasc Surg* 2007;**33**(4):453–60.
- 20 De Vivo S, Palmer-Kazen U, Kalin B, Wahlberg E. Risk factors for poor collateral development in claudication. *Vasc Endovasc Surg* 2005;**39**:519–24.
- 21 Eskelinen E, Lepäntalo M, Hietala EM, Sell H, Kauppila L, Mäenpää I, et al. Lower limb amputations in Southern Finland in 2000 and trends up to 2001. *Eur J Vasc Endovasc Surg* 2004;**27**:193–200.
- 22 IWGDF-PAD Working Group 2011. *Specific guidelines on diagnosis and treatment of PAD in the diabetic patient with a foot ulcer*. www.idf.org; 2011.
- 23 Norgren L, Hiatt WR, Dormandy JA, et al.; on behalf of the TASC II Working Group. Inter-Society Consensus for the Management of Peripheral Arterial Disease (TASC II). *J Vasc Surg* 2007;**45**(Suppl): S5–67.
- 24 LoGerfo FW, Coffman JD. Current concepts. Vascular and microvascular disease of the foot in diabetes. Implications for foot care. *N Engl J Med* 1984;**311**:1615–9.
- 25 Steed D, Attinger C, Colaizzi T, Crossland M, Franz M, Harkless L, et al. Guidelines for the treatment of diabetic ulcers. *Wound Rep Reg* 2006;**14**:680–92.
- 26 Schaper NC, Nabuurs-Franssen, MH, Huijberts SP. Peripheral vascular disease and type 2 diabetes mellitus. *Diabetes Metab Res Rev* 2000;**16**(Suppl 1): S11–5.
- 27 Schaper NC, Huijberts M, Pickwell K. Neurovascular control and neurogenic inflammation in diabetes. *Diabetes Metab Res Rev* 2008;**24**(Suppl 1):S40–4.
- 28 Jörneskog G, Brismar K, Fagrell B. Skin capillary circulation is more impaired in the toes of diabetic than non-diabetic patients with peripheral vascular disease. *Diabet Med* 1995;**12**(1):36–41.
- 29 Schaper NC. Diabetic foot ulcer classification system for research purposes: a progress report on criteria for including patients in research studies. *Diabetes Metab Res Rev* 2004;**20**(Suppl 1): 90–5.
- 30 Armstrong DG, Lavery LA, Harkless LB. Validation of a diabetic wound classification system. The contribution of depth, infection, and ischemia to risk of amputation. *Diabetes Care* 1998;**21**(5):855–9.
- 31 Beckert S, Witte M, Wicke C, et al. A new wound-based severity score for diabetic foot ulcers. *Diabetes Care* 2006;**29**(5):988–92.
- 32 Eneroth M, Larsson J, Apelqvist J. Foot infections in diabetes mellitus – entity with different characteristics, treatment and prognosis. *J Diabet Complications* 1999;**13**(5–6):254–63.
- 33 Lipsky BA, Berendt AR, Embil J, de Lalla F. Diagnosing and treating diabetic foot infections. *Diabetes Metab Res Rev* 2004;**20**(Suppl 1):S56–64.
- 34 Lipsky BA; International consensus group on diagnosing and treating the infected diabetic foot. A report from the international consensus on diagnosing and treating the infected diabetic foot. *Diabetes Metab Res Rev* 2004;**20**(Suppl 1): S68–77.

- 35 Boulton AJM. The diabetic foot: from art to science. *Diabetologia* 2004;**47**(8):1343–53.
- 36 Lundin M, Wiksten JP, Peräkylä T, Lindfors O, Savolainen H, Skyttä J, et al. Distal pulse palpation: is it reliable? *World J Surg* 1999;**23**:252–5.
- 37 Andros G, Harris RW, Dulawa LB, Oblath RW, Salles-Cunha SX. The need for arteriography in diabetic patients with gangrene and palpable foot pulses. *Arch Surg* 1984;**119**(11):1260–3.
- 38 McGee SR, Boyko EJ. Physical examination and chronic lower-extremity ischemia: a critical review. *Arch Intern Med* 1998;**158**(12):1357–64.
- 39 Boyko EJ, Ahroni JH, Davignon D, Stensel V, Prigeon RL, Smith DG. Diagnostic utility of the history and physical examination for peripheral vascular disease among patients with diabetes mellitus. *J Clin Epidemiol* 1997;**50**(6):659–68.
- 40 Karthikesalingam A, Holt PJ, Moxey P, Jones KG, Thompson MM, Hinchliffe RJ. A systematic review of scoring systems for diabetic foot ulcers. *Diabet Med* 2010;**27**(5):544–9.
- 41 Lavery LA, Armstrong DG, Harkless LB. Classification of diabetic foot wounds. *J Foot Ankle Surg* 1996;**35**(6):528–31.
- 42 International Working Group on the Diabetic Foot (IWGDF) Editorial Board. The Diabetic Foot. *Diabetes Metab Res Rev* 2008;**24**(Suppl 1):S1–193.
- 43 Cavanagh PR, Lipsky BA, Bradbury AW, Botek G. Treatment for diabetic foot ulcers. *Lancet* 2005;**366**:1725–35.
- 44 Eneroth M, Apelqvist J. Clinical characteristics and outcome in diabetic patients with deep foot infections. *Foot and Ankle* 1997;**18**:716–22.
- 45 Sapico FL, Witte JL, Canawati HN, Montgomerie JZ, Bessman AN. The infected foot of the diabetic patient: quantitative microbiology and analysis of clinical features. *Rev Infect Dis* 1984;**6**(Suppl 1):S171–6.
- 46 Pellizer G, Strazzabosco M, Presi S, Furlan F, Lora L, Benedetti P, et al. Deep tissue biopsy vs superficial swab culture monitoring in the microbiological assessment of limb-threatening diabetic foot infection. *Diabet Med* 2001;**18**:822–7.
- 47 Lipsky BA, Pecoraro RE, Larson SA, Hanley ME, Ahroni JH. Outpatient management of uncomplicated lower-extremity infections in diabetic patients. *Arch Intern Med* 1990;**150**:790–7.
- 48 Berendt AR, Peters EJ, Bakker K, Embil JM, Enenroth M, Hinchliffe RJ, et al. Diabetic foot osteomyelitis: a progress report on diagnosis and a systematic review of treatment. *Diabetes Metab Res Rev* 2008;**24**(Suppl 1):S145–61.
- 49 Lipsky BA, Berendt AR, Deery HG, Embil JM, Warren SJ, Karchmer AW, et al. Diagnosis and treatment of diabetic foot infections. *Clin Infect Dis* 2004;**39**:885–910.
- 50 Schaper NC, Andros G, Apelqvist J, Bakker K, Lammer J, Lepäntalo M, et al. *Diagnosis and treatment of peripheral arterial disease in diabetic patients with a foot ulcer. A Progress Report.* www.idf.org; 2011.
- 51 Faglia E, Clerici G, Clerissi J, Gabrielli L, Losa S, Mantero M, et al. Long-term prognosis of diabetic patients with critical limb ischemia: a population-based cohort study. *Diabetes Care* 2009;**32**(5):822–7.
- 52 Takolander R, Rauwerda JA. The use of noninvasive vascular assessment in diabetic patients with foot lesions. *Diab Med* 1995;**13**(Suppl 1):S39–42.
- 53 Levin ME. The diabetic neuropathic foot ulcer: pathogenesis, management, and prevention. In: Yao JST, Pearce WH (editors), *The Ischemic Extremity: Advances in Treatment.* Norwalk, Connecticut: Appleton & Lange; 1995, pp. 269–82.
- 54 Raines JK, Darling RC, Buth J, Brewster DC, Austen WG. Vascular laboratory criteria for the management of peripheral vascular disease of the lower extremities. *Surgery* 1976;**79**:21–9.
- 55 Vuorisalo S, Venermo M, Lepäntalo M. Treatment of diabetic foot ulcers. *J Cardiovasc Surg* 2009;**50**(3):275–91.
- 56 Mills Sr JL. Open bypass and endoluminal therapy: complementary techniques for revascularization in diabetic patients with critical limb ischaemia. *Diabetes Metab Res Rev* 2008;**24**(Suppl 1):S34–9.
- 57 Lukkari-Rautiainen E, Lepäntalo M, Pietilä J. Reproducibility of skin blood flow, perfusion pressure and oxygen tension measurements in advanced lower limb ischaemia. *Eur J Vasc Surg* 1989;**3**:345–50.
- 58 Armstrong DG, Lavery LA; Diabetic Foot Study Consortium. Negative pressure wound therapy after partial diabetic foot amputation: a multicentre, randomised controlled trial. *Lancet* 2005;**366**:1704–10.
- 59 Faglia E, Clerici G, Caminiti M, Quarantiello A, Curci V, Morabito A. Predictive values of transcutaneous oxygen tension for above-the-ankle amputation in diabetic patients with critical limb ischemia. *Eur J Vasc Endovasc Surg* 2007;**33**:731–6.
- 60 Padberg FT, Back TL, Thompson PN, Hobson 2nd RW. Transcutaneous oxygen (TcPO₂) estimates probability of healing in the ischemic extremity. *J Surg Res* 1996;**60**:365–9.
- 61 Collins R, Burch J, Cranny G, Aguiar-Ibáñez R, Craig D, Wright K, et al. Duplex ultrasonography, magnetic resonance angiography, and computed tomography angiography for diagnosis and assessment of symptomatic, lower limb peripheral arterial disease: systematic review. *BMJ* 2007;**334**(7606):1257.
- 62 Catalano C, Fraioli F, Laghi A, Napoli A, Bezzi M, Pediconi F, et al. Infra-renal aortic and lower-extremity arterial disease: diagnostic performance of multi-detector row CT angiography. *Radiology* 2004;**231**(2):555–63.
- 63 Romano M, Mainenti PP, Imbriaco M, Amato B, Markabaoui K, Tamburrini O, et al. Multidetector row CT angiography of the abdominal aorta and lower extremities in patients with peripheral arterial occlusive disease: diagnostic accuracy and interobserver agreement. *Eur J Radiol* 2004;**50**(3):303–8.
- 64 Adriaensen ME, Kock MC, Stijnen T, van Sambeek MR, van Urk H, Pattynama PM, et al. Peripheral arterial disease: therapeutic confidence of CT versus digital subtraction angiography and effects on additional imaging recommendations. *Radiology* 2004;**233**(2):385–91.
- 65 Prince MR, Zhang H, Morris M, MacGregor JL, Grossman ME, Silberzweig J, et al. Incidence of nephrogenic systemic fibrosis at two large medical centers. *Radiology* 2008;**248**(3):807–16.
- 66 Rydahl C, Thomsen HS, Marckmann P. High prevalence of nephrogenic systemic fibrosis in chronic renal failure patients exposed to gadodiamide, a gadolinium-containing magnetic resonance contrast agent. *Invest Radiol* 2008;**43**(2):141–4.
- 67 Wertman R, Altun E, Martin DR, Mitchell DG, Leyendecker JR, O'Malley RB, et al. Risk of nephrogenic systemic fibrosis: evaluation of gadolinium chelate contrast agents at four American universities. *Radiology* 2008;**248**(3):799–806.
- 68 Bollinger A, Breddin K, Hess H, Heystraten FM, Kollath J, Konttila A, et al. Semiquantitative assessment of lower limb atherosclerosis from routine angiographic images. *Atherosclerosis* 1981;**38**(3–4):339–46.
- 69 Bradbury AW, Adam DJ, Bell J, Forbes JF, Fowkes FG, Gillespie I, et al.; BASIL trial Participants. Bypass versus Angioplasty in Severe Ischaemia of the Leg (BASIL) trial: A description of the severity and extent of disease using the Bollinger angiogram scoring method and the TransAtlantic Inter-Society Consensus II classification. *J Vasc Surg* 2010;**51**(5 Suppl):325–42S.
- 70 Kukkonen T, Korhonen M, Halmesmäki K, Lehti L, Tiitola M, Aho P, et al. Poor inter-observer agreement on the TASC II classification of femoropopliteal lesions. *Eur J Vasc Endovasc Surg* 2010 Feb;**39**(2):220–4.
- 71 Zimmermann A, Wendorff H, Schuster T, Auer F, Berger H, Eckstein HH. Interobserver agreement of the TASC II

- classification for supra- and infrainguinal lesions. *Eur J Vasc Endovasc Surg* 2010 May; **39**(5):586–90.
- 72 Heikkinen M, Salmenperä M, Lepäntalo A, Lepäntalo M. Diabetes care for patients with peripheral arterial disease. *Eur J Vasc Endovasc Surg* 2007; **33**:583–91.
 - 73 Pomposelli F. Arterial imaging in patients with lower extremity ischemia and diabetes mellitus. *J Vasc Surg* 2010; **52**(3 Suppl): 81S–91S.
 - 74 Ascher E, Marks NA, Hingorani AP, Schutzer RW, Nahata S. Duplex-guided balloon angioplasty and subintimal dissection of infra-popliteal arteries: early results with a new approach to avoid radiation exposure and contrast material. *J Vasc Surg* 2005; **42**: 1114–21.
 - 75 American Diabetes Association (ADA). Standards of medical care in diabetes – 2006. *Diabetes Care* 2006; **29**(Suppl 1):S4–42.
 - 76 Muntner P, Wildman RP, Reynolds K, Desalvo KB, Chen J, Fonseca V. Relationship between HbA1c level and peripheral arterial disease. *Diabetes Care* 2005; **28**:1981–7.
 - 77 Lipsky BA. Evidence-based antibiotic therapy of diabetic foot infections. *FEMS Immunol Med Microbiol* 1999; **26**:267–76.
 - 78 Berendt AR, Peters EJ, Bakker K, Embil JM, Eneroth M, Hinchliffe RJ, et al. Specific guidelines for treatment of diabetic foot osteomyelitis. *Diabetes Metab Res Rev* 2008; **24**(Suppl 1):S190–1.
 - 79 Söderström M, Arvela EM, Korhonen M, Halmesmäki KH, Albäck AN, Biancari F, et al. Infrapopliteal percutaneous transluminal angioplasty versus bypass surgery as first-line strategies in critical leg ischemia: a propensity score analysis. *Ann Surg* 2010; **252**(5):765–73.
 - 80 Faglia E, Clerici G, Clerissi J, Mantero M, Caminiti M, Quarantiello A, et al. When is a technically successful peripheral angioplasty effective in preventing above-the-ankle amputation in diabetic patients with critical limb ischaemia? *Diabet Med* 2007; **24**:823–9.
 - 81 Fransson T, Thörne J. In situ saphenous vein bypass grafting – still first line treatment? A prospective study comparing surgical results between diabetic and non-diabetic populations. *Vasa* 2010; **39**:59–65.
 - 82 Sigala F, Menenakos Ch, Sigalas P, Baunach Ch, Langer S, Papalambros E, et al. Transluminal angioplasty of isolated crural arterial lesions in diabetics with critical limb ischemia. *Vasa* 2005; **34**:186–91.
 - 83 Met R, Van Lienden KP, Koelmay MJ, Bipat S, Legemate DA, Reekers JA. Subintimal angioplasty for peripheral arterial occlusive disease: a systematic review. *Cardiovasc Intervent Radiol* 2008; **31**:687–97.
 - 84 Dosluoglu HH, Cherr GS, Lall P, Harris LM, Dryjski ML. Peroneal artery-only runoff following endovascular revascularizations is effective for limb salvage in patients with tissue loss. *J Vasc Surg* 2008; **48**:137–43.
 - 85 Faglia E, Dalla Paola L, Clerici G, Clerissi J, Graziani L, Fusaro M, et al. Peripheral angioplasty as the first-choice revascularization procedure in diabetic patients with critical limb ischemia: prospective study of 993 consecutive patients hospitalized and followed between 1999 and 2003. *Eur J Vasc Endovasc Surg* 2005; **29**(6):620–7.
 - 86 Graziani L, Piaggese A. Indications and clinical outcomes for below knee endovascular therapy: review article. *Catheter Cardiovasc Interv* 2010; **75**(3):433–43.
 - 87 Manzi M, Fusaro M, Ceccacci T, Erente G, Dalla Paola L, Brocco E. Clinical results of below-the knee intervention using pedal-plantar loop technique for the revascularization of foot arteries. *J Cardiovasc Surg* 2009; **50**(3):331–7.
 - 88 Fusaro M, Dalla Paola L, Biondi-Zoccai G. Pedal-plantar loop technique for a challenging below-the-knee chronic total occlusion: a novel approach to percutaneous revascularization in critical lower limb ischemia. *J Invasive Cardiol* 2007; **19**(2): E34–7.
 - 89 Graziani L, Silvestro A, Monge L, Boffano GM, Kokaly F, Casadidio I, et al. Transluminal angioplasty of peroneal artery branches in diabetics: initial technical experience. *Cardiovasc Intervent Radiol* 2008; **31**(1):49–55.
 - 90 Alexandrescu VA, Hubermont G, Philips Y, Guillaumie B, Ngongang C, Vandenbossche P, et al. Selective primary angioplasty following an angiosome model of reperfusion in the treatment of Wagner 1–4 diabetic foot lesions: practice in a multidisciplinary diabetic limb service. *J Endovasc Ther* 2008; **15**(5):580–93.
 - 91 Setacci C, de Donato G, Setacci F, Chisci E. Ischemic foot: definition, etiology and angiosome concept. *J Cardiovasc Surg* 2010; **51**(2):223–31.
 - 92 Neville RF, Attinger CE, Bulan EJ, Ducic I, Thomassen M, Sidawy AN. Revascularization of a specific angiosome for limb salvage: does the target artery matter? *Ann Vasc Surg* 2009; **23**(3):367–73.
 - 93 Attinger CE, Evans KK, Bulan E, Blume P, Cooper P. Angiosomes of the foot and ankle and clinical implications for limb salvage: reconstruction, incisions, and revascularization. *Plast Reconstr Surg* 2006; **117**(7 Suppl):261S–293S.
 - 94 Lepäntalo M, Biancari F, Tukiainen E. Never amputate without consultation of a vascular surgeon. *Diabetes Metab Res Rev* 2000; **16**(Suppl 1):S27–32.
 - 95 Pomposelli FB, Kansal N, Hamdan AD, Belfield A, Sheahan M, Campbell DR, et al. A decade of experience with dorsalis pedis artery bypass: analysis of outcome in more than 1000 cases. *J Vasc Surg* 2003; **37**:307–15.
 - 96 Biancari F, Kantonen I, Alback A, Matzke S, Luther M, Lepäntalo M. Limits of infrapopliteal bypass surgery for critical leg ischemia: when not to reconstruct. *World J Surg* 2000; **24**:727–33.
 - 97 Hinchliffe RJ, Andros G, Apelqvist J, Bakker K, Friedrichs S, Lammer J, et al. *A systematic review of the effectiveness of revascularisation of the ulcerated foot in patients with diabetes and peripheral arterial disease.* www.idf.org; 2011.
 - 98 Ihnat DM, Mills Sr JL. Current assessment of endovascular therapy for infrainguinal arterial occlusive disease in patients with diabetes. *J Vasc Surg* 2010; **52**(Suppl 3):92S–95S.
 - 99 Rosenblum BI, Pomposelli FB, Giurini JM, Gibbons GW, Freeman D, Chrzan JS, et al. Maximizing foot salvage by a combined approach to foot ischemia and neuropathic ulceration in patients with diabetes. *Diabetes Care* 1994; **17**:983–7.
 - 100 Wölfle KD, Buijnen H, Reeps C, Reutemann S, Wack C, Campbell P, et al. Tibioperoneal arterial lesions and critical foot ischaemia: successful management by the use of short vein grafts and percutaneous transluminal angioplasty. *Vasa* 2000; **29**:207–14.
 - 101 Schneider PA, Caps MT, Ogawa DY, Hayman ES. Intraoperative superficial femoral artery balloon angioplasty and popliteal to distal bypass graft: An option for combined open and endovascular treatment of diabetic gangrene. *J Vasc Surg* 2001; **33**:955–62.
 - 102 Faglia E, Mantero M, Caminiti M, Caravaggi C, de Giglio R, Pritelli C, et al. Extensive use of peripheral angioplasty, particularly infrapopliteal, in the treatment of ischaemic diabetic foot ulcers: clinical results of a multicentric study of 221 consecutive diabetic subjects. *J Intern Med* 2002; **252**:225–32.
 - 103 Dorweiler B, Neufang A, Schmiedt W, Oelert H. Pedal arterial bypass for limb salvage in patients with diabetes mellitus. *Eur J Vasc Endovasc Surg* 2002; **24**:309–13.
 - 104 Bargellini I, Petrucci P, Scatena A, Cioni R, Cicorelli A, Vignali C, et al. Primary infrainguinal subintimal angioplasty in diabetic patients. *Cardiovasc Intervent Radiol* 2008; **31**:713–22.
 - 105 Ferraresi R, Centola M, Ferlini M, Da Ros R, Caravaggi C,

- Assaloni R, et al. Long-term outcomes after angioplasty of isolated, below-the-knee arteries in diabetic patients with critical limb ischaemia. *Eur J Vasc Endovasc Surg* 2009;**37**:336–42.
- 106 Albers M, Romiti M, Brochado-Neto FC, De Luccia N, Pereira CA. Meta-analysis of popliteal-to-distal vein bypass grafts for critical ischemia. *J Vasc Surg* 2006;**43**:498–503.
- 107 Romiti M, Albers M, Brochado-Neto FC, Durazzo AE, Pereira CA, De Luccia N. Meta-analysis of infrapopliteal angioplasty for chronic critical limb ischemia. *J Vasc Surg* 2008;**47**:975–81.
- 108 Adam DJ, Beard JD, Cleveland T, Bell J, Bradbury AW, Forbes JF, et al.; on behalf of the BASIL trial participants. Bypass versus angioplasty in severe ischaemia of the leg (BASIL): multicentre, randomised controlled trial. *Lancet* 2005;**366**:1925–34.
- 109 Fitzgerald O'Connor EJ, Vesely M, Holt PJ, Jones KG, Thompson MM, Hinchliffe RJ. A systematic review of free tissue transfer in the management of non-traumatic lower extremity wounds in patients with diabetes. *Eur J Vasc Endovasc Surg* 2011;**41**(3):391–9.
- 110 Tukiainen E, Kallio M, Lepantalo M. Advanced leg salvage of the critically ischemic leg with major tissue loss by vascular and plastic surgeon teamwork: Long-term outcome. *Ann Surg* 2006;**244**:949–57.
- 111 Tannenbaum GA, Pomposelli Jr FB, Marcaccio EJ, Gibbons GW, Campbell DR, Freeman DV, et al. Safety of vein bypass grafting to the dorsal pedal artery in diabetic patients with foot infections. *J Vasc Surg* 1992;**15**:982–8.
- 112 Chang BB, Darling RC, Paty PSK, Lloyd WE, Shah DM, Leather RP. Expedient management of ischemic invasive foot infections. *Cardiovasc Surg* 1996;**4**:792–5.
- 113 Sheahan MG, Hamdan AD, Veraldi JR, McArthur CS, Skillman JJ, Campbell DR, et al. Lower extremity minor amputations: the roles of diabetes mellitus and timing of revascularization. *J Vasc Surg* 2005;**42**:476–80.
- 114 Hinchliffe RJ, Valk GD, Apelqvist J, Armstrong DG, Bakker K, Game FL, et al. A systematic review of the effectiveness of interventions to enhance the healing of chronic ulcers of the foot in diabetes. *Diabetes Metab Res Rev* 2008;**24**(Suppl 1):S119–44.
- 115 Smith J. Debridement of diabetic foot ulcers. *Cochrane Database Syst Rev* 2002;(4):CD003556.
- 116 Bergin SM, Wraight P. Silver based wound dressings and topical agents for treating diabetic foot ulcers. *Cochrane Database Syst Rev* 2006;(1):CD005082.
- 117 Löndahl M, Katzman P, Nilsson A, Hammarlund C. Hyperbaric oxygen therapy facilitates healing of chronic foot ulcers in patients with diabetes. *Diabetes Care* 2010;**33**:998–1003.
- 118 Faglia E, Favales F, Aldeghi A, Calia P, Quarantiello A, Oriani G, et al. Adjunctive systemic hyperbaric oxygen therapy in treatment of severe prevalently ischemic diabetic foot ulcer. A randomized study. *Diabetes Care* 1996;**19**:1338–43.
- 119 Abidia A, Laden G, Kuhan G, Johnson BF, Wilkinson AR, Renwick PM, et al. The role of hyperbaric oxygen therapy in ischaemic diabetic lower extremity ulcers: a double-blind randomised-controlled trial. *Eur J Vasc Endovasc Surg* 2003;**25**:513–8.
- 120 Tan T, Shaw EJ, Siddiqui F, Kandaswamy P, Barry PW, Baker M; Guideline Development Group. Inpatient management of diabetic foot problems: summary of NICE guidance. *BMJ* 2011;**342**:702–3.
- 121 Vikatmaa P, Juutilainen V, Kuukasjärvi P, Malmivaara A. Negative pressure wound therapy: a systematic review on effectiveness and safety. *Eur J Vasc Endovasc Surg* 2008;**36**:438–48.
- 122 Ubbink DT, Westerbos SJ, Nelson EA, Vermeulen H. A systematic review of topical negative pressure therapy for acute and chronic wounds. *Br J Surg* 2008;**95**:685–92.
- 123 Game F. The advantages and disadvantages of non-surgical management of the diabetic foot. *Diabetes Metab Res Rev* 2008;**24**(Suppl 1):S72–5.
- 124 Frykberg RG, Armstrong DG, Giurini J, Edwards A, Kravette M, Kravitz S, et al.; American College of Foot and Ankle Surgeons. Diabetic foot disorders: a clinical practice guideline. American College of Foot and Ankle Surgeons. *J Foot Ankle Surg* 2000;**39**(Suppl 5):S1–60.
- 125 Pollard J, Hamilton GA, Rush SM, Ford LA. Mortality and morbidity after transmetatarsal amputation: retrospective review of 101 cases. *J Foot Ankle Surg* 2006;**45**(2):91–7.
- 126 Stone PA, Back MR, Armstrong PA, Flaherty SK, Keeling WB, Johnson BL, et al. Midfoot amputations expand limb salvage rates for diabetic foot infections. *Ann Vasc Surg* 2005;**19**(6):805–11.
- 127 Dalla Paola L, Faglia E, Caminiti M, Clerici G, Ninkovic S, Deanesi V. Ulcer recurrence following first ray amputation in diabetic patients: a cohort prospective study. *Diabetes Care* 2003;**26**(6):1874–8.
- 128 Abou-Zamzam Jr AM, Gomez NR, Molkara A, Banta JE, Teruya TH, Killeen JD, et al. A prospective analysis of critical limb ischemia: factors leading to major primary amputation versus revascularization. *Ann Vasc Surg* 2007;**21**(4):458–63.
- 129 Söderström M, Arvela E, Albäck A, Aho PS, Lepäntalo M. Healing of ischaemic tissue lesions after infrainguinal bypass surgery for critical leg ischaemia. *Eur J Vasc Endovasc Surg* 2008;**36**:90–5.
- 130 Apelqvist J, Elgzyri T, Larsson J, Löndahl M, Nyberg P, Thörne J. Factors related to outcome of neuroischemic/ischemic foot ulcer in diabetic patients. *J Vasc Surg* 2011;**53**(6):1582–8.
- 131 Lepäntalo M, Mätzke S. Outcome of unreconstructed chronic critical leg ischaemia. *Eur J Vasc Endovasc Surg* 1996;**11**(2):153–7.
- 132 Venermo M, Biancari F, Arvela E, Korhonen M, Söderström M, Halmesmäki K, et al. The role of chronic kidney disease as a predictor of outcome after revascularisation of the ulcerated diabetic foot. *Diabetologia* 2011 [Epub Aug 16, 2011].
- 133 Khan MU, Lall P, Harris LM, Dryjski ML, Dosluoglu HH. Predictors of limb loss despite a patent endovascular-treated arterial segment. *J Vasc Surg* 2009;**49**:1440–5.
- 134 Khalifa AA, Gueret G, Badra A, Gouny P. Diabetic critical ischemia of lower limbs: distal arterial revascularisation. *Acta Chir Belg* 2009;**109**(3):321–6.
- 135 Lumsden AB, Davies MG, Peden EK. Medical and endovascular management of critical limb ischemia. *J Endovasc Ther* 2009;**16**(2 Suppl 2):II31–62.
- 136 Taylor SM, York JW, Cull DL, Kalbaugh CA, Cass AL, Langan 3rd EM. Clinical success using patient-oriented outcome measures after lower extremity bypass and endovascular intervention for ischemic tissue loss. *J Vasc Surg* 2009;**50**(3):534–41.
- 137 Sibbald R, Woo K. The biology of chronic foot ulcers in persons with diabetes. *Diabetes Metab Res Rev* 2008;**24**(Suppl 1):S25–30.